

7本足の子ウシ-殿部に付着する過剰前肢をもつ二殿体

誌名	Japanese journal of veterinary science
ISSN	00215295
著者	平賀, 武夫 阿部, 光雄 岩佐, 憲二
巻/号	51巻5号
掲載ページ	p. 1011-1015
発行年月	1989年10月

Seven-Legged Calf—Dipygus with an Extra Foreleg at the Pelvic Region

Takeo HIRAGA, Mitsuo ABE, Kenji IWASA, Kazushige TAKEHANA, and Makoto TETSUKA

Department of Veterinary Anatomy, Rakuno Gakuen University, 582-1 Bunkyo-dai Midorimachi, Ebetsu 069, Japan

(Received 10 May 1989/Accepted 26 July 1989)

ABSTRACT. A male Holstein-Friesian calf with seven legs was examined macroscopically and radiographically. External features included two normal forelimbs, two normal hindlimbs (lateral hindlimbs), and two abnormal hindlimbs (medial hindlimbs) which were underdeveloped. Also, a rudimentary forelimb, which was attached to the pelvic region, was observed between both the medial hindlimbs. It consisted of an underdeveloped humerus, a duplicated ulna, several carpal bones, a partially duplicated metacarpal bone and three digits with three hoofs. This leg was connected with two sets of coxae by an irregular-shaped bone considered the vestigial vertebrae and ribs. Two penises and scrotums, three kidneys and testes were also observed. This calf is the first case of dipygus associated with pygopagus parasiticus in cattle. Based on these findings, the pathogenesis of this rare anomaly was briefly discussed from an embryological point of view.—**KEY WORDS:** calf, congenital anomaly, dipygus, pygopagus parasiticus.

Jpn. J. Vet. Sci. 51(5): 1011-1015, 1989

Various types of attached symmetrical twins in cattle have six [4, 12, 15, 16, 18] or eight legs [1, 6, 7, 13, 14, 17, 20] according to the degree of their attachment. Heterotopic polymelia has one or two supernumerary legs attached to the various body region and is classified accordingly: notomelia, cephalomelia, thoracomelia and pygomelia [19]. Therefore, they have five or six legs [2, 10, 18, 21, 22].

Recently we found a calf with seven legs while investigating many other anomalous calves [11]. To the authors' knowledge, there have been only two case reports on this anomaly in cattle [8, 25]. The purpose of this article is to describe in detail the anatomical findings on this rare anomaly and to discuss the conceivable pathogenesis from an embryological point of view.

MATERIALS AND METHODS

A 7-year-old Holstein-Friesian cow, which had previously given birth to 4 normal calves, delivered a stillborn anomalous male calf weighing 48 kg. The calf was sent to our

department as object of study, and necropsied immediately after his arrival. Before necropsy, 2% formalin solution was perfused via the left common carotid artery. The skeletal systems were radiographed, using soft X-ray (SOFTEX K-2 type), and/or prepared by maceration for detailed observation.

RESULTS

External features included seven-legs; two normal forelimbs, two normal hindlimbs (lateral hindlimbs), two abnormally less developed hindlimbs (medial hindlimbs) and a rudimentary central limb with three digits and three hoofs distally (Figs. 1 and 2); however, other parts of the body had an almost normal appearance. Between both sides of lateral and medial hindlimbs, two penises and two scrotums were seen. An anus was not perforated.

A urinary bladder, two urethra and an extra small kidney (Fig. 3) were seen in an open pelvic cavity consisted of two sets of coxae and one sacrum. Four acetabulums

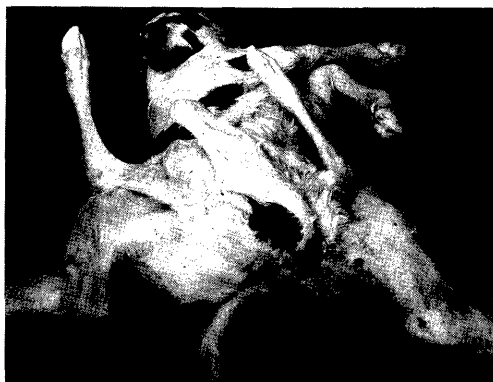

Fig. 1. External appearance of an anomalous calf showing two forelimbs, four hindlimbs and a central limb. The tail is single.

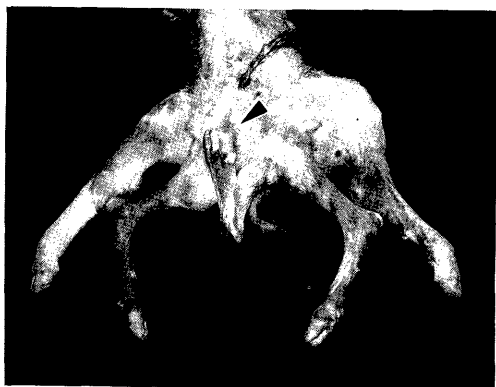

Fig. 2. Ventral view of the caudal part. The central limb is rudimentary and has three hoofs (arrowhead) distally.

formed four hip joints with each heads of four femurs (Fig. 4). Two ductus deferences extending from the two testes, located under the skin, opened together only into the left urethra, and only one set of accessory genital glands was associated with this urethra. An extra testis located beneath the skin of the region, where the central limb attached to the pelvis, had no other organs such as the epididymis and the ductus deference.

A row of coccygeal vertebrae-like bones which extended from the coccygeal vertebrae (Fig. 5) connected with the proximal bone of the central limb. This bone, measuring $13.5 \times 7.5 \times 4.5$ cm, was articulated

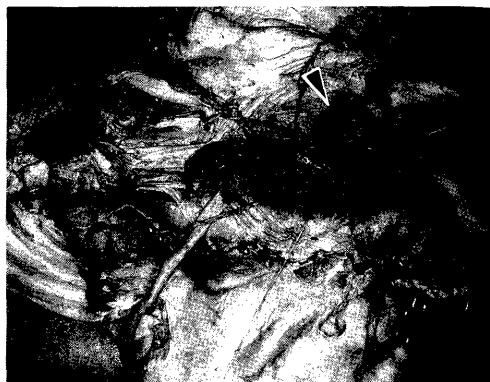


Fig. 3. Pelvic cavity is not closed. An extra kidney (arrowhead) is located in this cavity.

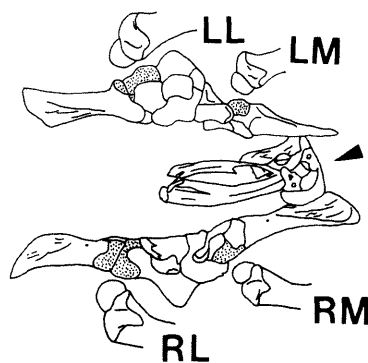


Fig. 4. Schematic diagram illustrating two sets of coxae, left lateral (LL) and medial (LM), right lateral (RL) and medial (RM) hindlimbs, Arrowhead shows proximal bone articulating with the coxae. [•••]: acetabulums.

with coxae and had irregular form, which consisted of three main parts; vertebrae-, rib- and bended board-like parts (Figs. 4 and 6). The following bone of the central limb was slender and was attached to the proximal bone by only soft tissue, without any articular structure. It had a small head proximally and an epicondyle distally, which articulated with the next duplicated ulna-like bone without vestiges of radius (Fig. 7). The incompletely duplicated metacarpal bone was possessed of two dorsal longitudinal grooves, and three rows of the digits were also observed (Fig. 8). Several small irregular bones, which seemed to be carpal

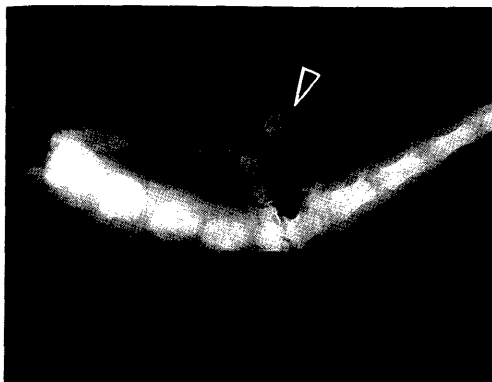


Fig. 5. X-ray film of the sacral and coccygeal vertebrae. A row of coccygeal vertebrae-like bones (arrowhead) extends from the coccygeal vertebrae.

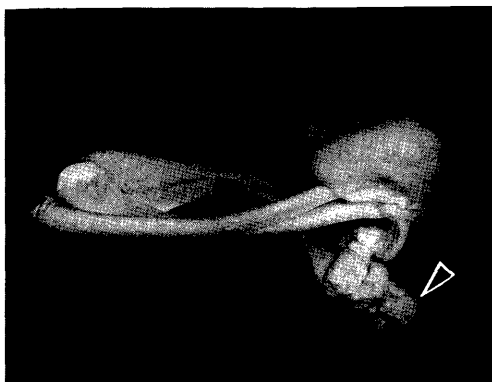


Fig. 6. Proximal bone of the central limb consists of a mass and rib-like bone. A part of this bone (arrowhead) is connected with the vertebrae-like bone showed in Figure 5 by arrowhead.

bones, lay between the ulna-like bone and metacarpal bone (Fig. 9).

DISCUSSION

Dipygus: Attached symmetrical twins reportedly occur in one of 100,000 bovine births and these anomalies have been involved the anterior part of the body more frequently than the posterior part [3, 23]. Moreover, Leipold *et al.* [18] reported only one case of dipygus out of 28 anomalous twins in calves. Therefore, dipygus appears to be a rare malformation in calves as suggested by Dämmrich [5]. Therefore, only

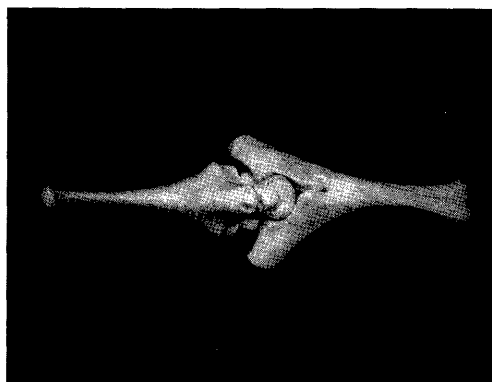


Fig. 7. A slender bone (left) and duplicated ulna-like bone (right) of the central limb. Both bones articulate with each other. Radius-like bone is not detected.

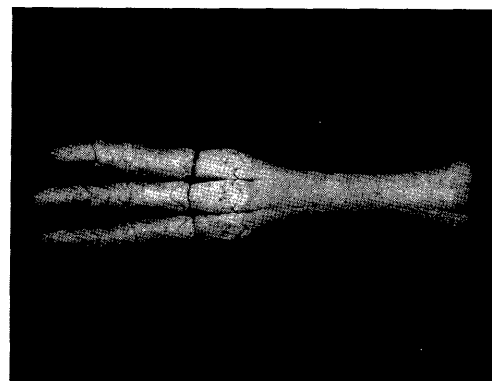


Fig. 8. Incompletely duplicated metacarpal bone and three rows of the digits. Two dorsal longitudinal grooves are seen.

a few reports concerned with dipygus are seen in cattle [4, 5, 13, 18]. Among them, only Leipold *et al.* [18] described detailed anatomical findings of a female calf as follows: The calf has six legs; four of them are normal legs and two of them are accessory hindlegs attached to the normal pelvis. One as large as a normal hindleg, the other smaller. Both the vagina and anus are duplicated. We described for the first time symmetrical two sets of hindlegs, two penises, two scrotums and an extra testis and kidney on male calf.

Central leg: Abt *et al.* [2] reported a calf possessing an unpaired extra limb attached

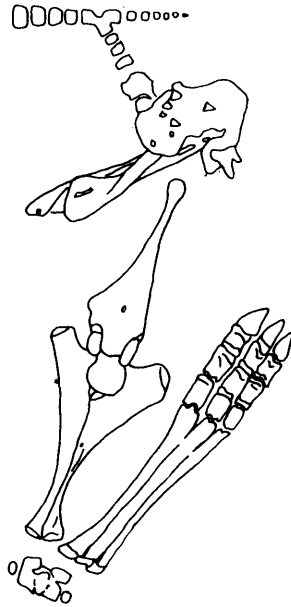


Fig. 9. Schematic diagram illustrating caudal vertebrae and all the bone of the central limb. Several small irregular bones exist between the ulna-like and metacarpal bone.

to the pelvic region. They called this case as dipygus parasiticus according to the presence of the rudimentary coxae-like bone proximally to the leg. Because of the connection with the coccygeal vertebrae and its vertebrae- and rib-like appearance, the most proximal irregular bone of the central limb observed in this study were supposed as rudimentary vertebrae fused with a few ribs. The next slender bone was considered to be the underdeveloped humerus based on its shape. Ueshima and Uehara [24] reported a bovine case of ulnar dimelia and described a rudimentary radius caught between two ulnas. Also they reported fused metacarpal bones and four rows of the digits. An extra limb of present case was supposed to be ulnar dimelia showing the higher degree of fusion than their case.

Seven legs: There have been only two case reports concerning seven-legged calves. Ehlers [8] briefly mentioned that a male calf had two heads, two forelegs, four hindlegs

and a fifth rudimentary leg (18 inches long, hoof fused) between them. On the other hand, Wacker and Gläser [25] described anatomical findings of a male calf affected with dicephalus tribrachius tetrapus, which has two heads, three forelegs and four hindlegs. Present case bears a close resemblance to a Ehlers's case; however, he referred to the rudimentary leg as hindleg without detail findings. The seven-legged calf observed in this study is unique because the central leg, which is attached to the pelvic region, is believed to be a foreleg.

In conclusion, the present case is thought to be dipygus associated with a very intriguing parasite attached to the pelvic region (pygopagus parasiticus). According to Evans and Sack [9], the neural tube closes at 23 days and the forelimb bud occurs at 24 days of gestation in cattle. Therefore, in early embryological stage, the anlage of the extra thoracic vertebrae with a few ribs may develop at the caudal region of the normal body before or after the normal vertebral column differentiate into the cervical to coccygeal vertebrae, and simultaneously two forelimb buds probably arise at the distal part of these anlage.

ACKNOWLEDGEMENTS. The authors wish to thank the veterinarians of Nishimon Agricultural Mutual Aid Association, Okoppe, for supplying the calf.

REFERENCES

1. Abe, M., Hiraga, T., Iwasa, K., Numata, Y., Kotani, T., and Ando, Y. 1978. A case of bovine thoracopagus. *J. Coll. Dairying* 7: 331-336 (in Japanese).
2. Abt, D. A., Droshaw, J. E. Jr., and Hare, W. C. D. 1962. Monocephalus dipygus parasiticus and other anomalies in a calf. *J. Am. Vet. Med. Assoc.* 141: 1068-1072.
3. Arthur, G. H. 1956. Conjoined twins-The veterinary aspect. *Vet. Rec.* 68: 389-393.
4. Bhattacharyya, M. M. 1964. Six-legged monster in a calf. *Ind. Vet. J.* 41: 739.
5. Dämmrich, K. 1985. Entwicklungsstörungen des Skeletts. pp. 482-642. *In: Handbuch der Spezial-*

- len Pathologischen Anatomie der Haustiere, 3rd ed., Vol.4 (Dobberstein, J., Pallaske, G., and Stünzi, H. eds.), Paul Parey, Berlin.
6. Dransfield, J. W. and Pinsent, P. J. N. 1956. A case of cephalothoracopagus monosymmetros in the bovine species, from the clinical and anatomical aspects. *Br. Vet. J.* 112: 300-304 and 416-423.
 7. Dunn, D. G. and Moreland, R. E. 1983. Conjoined twins in a bovine fetus. *Vet. Med. Small Anim. Clin.* 78: 1441-1444.
 8. Ehlers, D. P. 1939. Unusual bovine monster. *Vet. Med.* 34: 96.
 9. Evans, H. E. and Sack, W. O. 1973. Prenatal development of domestic and laboratory mammals: Growth curves, external features and selected references. *Anat. Histol. Embryol.* 2: 11-45.
 10. Graves, R. R. 1947. Twin bull calves—One an anomaly. *J. Am. Vet. Med. Assoc.* 110: 370-374.
 11. Hiraga, T., Abe, M., Iwasa, K., and Takehana, K. 1987. Morphological study of bovine congenital defects in Hokkaido over the last eleven years. *J. Coll. Dairying* 12: 257-268 (in Japanese).
 12. Hirsch, J., Okyere, K., and Sobiraj, A. 1982. Ein Fall von Siamesischen Zwillingen beim Rind. *Berl. Muench. Tieraerztl. Wochenschr.* 95: 478-480.
 13. Hoch, R. J. 1956. Bovine monstrosity. *North Am. Vet.* 37: 854.
 14. Hofmann, W. 1969. A bovine double monster-Omphalopagus. *Vet. Med. Rev.* 40:308-312.
 15. Hughes, H. V. 1946. A case of duplicitas in a calf. *Vet. J.* 102: 227-234.
 16. Johansson, I. and Venge, O. 1951. Studies on the value of various morphological characters for the diagnosis of monozygosity of cattle twins. *Z. Tierz. Zuechtungsbiol.* 59: 389-429.
 17. Krueger, E. W. 1954. Bovine dystocia due to siamese twins. *J. Am. Vet. Med. Assoc.* 124: 107.
 18. Liepold, H. W., Dennis, S. M., and Huston, K. 1972. Embryonic duplications in cattle. *Cornell Vet.* 62: 572-580.
 19. Leipold, H. W., Huston, K., and Dennis, S. M. 1983. Bovine congenital defects. *Adv. Vet. Sci. Comp. Med.* 27: 197-271.
 20. Petersen, R. J. and de Boom, H. P. A. 1970. Siamese twins (Thoracopagus). *J. S. Afr. Vet. Med. Assoc.* 41: 69-70.
 21. Pohlmeier, K. 1975. Notomelie beim Kalb. *Dtsch. Tieraerztl. Wochenschr.* 82: 190-195.
 22. Rieke, H. and Allmacher, E. 1982. Die operative Behandlung der Notomelie (Kurzzusammenfassung). *Dtsch. Tieraerztl. Wochenschr.* 89: 113-114.
 23. Roberts, S. J. 1971. Veterinary Obstetrics and Genital Diseases (Theriogenology), 2nd ed., Edwards Brothers, Ann Arbor.
 24. Ueshima, T. and Uehara, M. 1981. Ulnar dimelia in a calf. *Jpn. J. Vet. Sci.* 43: 351-357.
 25. Wacker, R. and Gläser, H. 1988. Dicephale Doppelmilßbildung beim Rind: Dicephalus tribrachius tetrapus. *Tieraerztl. Umsch.* 43: 248-252.

要 約

7本足の子ウシ-殿部に付着する過剰前肢をもつ二殿体：平賀武夫・阿部光雄・岩佐憲二・竹花一成・手塚 誠(酪農学園大学家畜解剖学教室)——7本の足をもつた1例のホルスタイン種雄子ウシを肉眼的およびX線学的に観察した。外観上、2本の正常な前肢、2本の正常な外側後肢、2本の発達の悪い内側後肢および1本の殿部に付着する過剰前肢がみられた。この過剰前肢は発達の悪い上腕骨、重複した尺骨、数個の手根骨、部分的に重複した中手骨および3個の蹄をもつた3列の指骨から構成されていた。この肢は、痕跡的な脊柱および肋骨と考えられる不規則な形をした骨を介して寛骨に付着していた。寛骨は2組存在していた。陰茎、陰囊は重複しており、腎臓と精巣は3個認められた。本例は寄生性殿結合体と二殿体の合併したウシの初めての報告である。この極めて珍しい先天異常の発生機序を簡潔に考察した。