

## 発作を主訴とする犬の電気生理学的および病理学的研究

誌名	Japanese journal of veterinary science
ISSN	00215295
著者	宇塚, 雄次 中畑, 功一郎 竹田, 良子
巻/号	51巻5号
掲載ページ	p. 1055-1058
発行年月	1989年10月

## Electrophysiological and Pathological Study in a Dog with Seizure

Yuji UZUKA, Kouichirou NAKAHATA, Yoshiko TAKEDA, and Naoaki GOTO<sup>1)\*</sup>

Department of Veterinary Internal Medicine and <sup>1)Department of Veterinary Pathology, Faculty of Agriculture, Yamaguchi University, Yamaguchi 753, Japan</sup>

(Received 19 August 1988/Accepted 27 June 1989)

*Jpn. J. Vet. Sci.* 51(5): 1055-1058, 1989

**KEY WORDS:** dog, electroencephalogram, meningoencephalitis.

Electroencephalogram (EEG) examination has been performed in clinical veterinary medicine [1, 5]. Recently, the knowledge of systematic electroencephalography was reported by Redding and Knecht [6]. Klemm reported EEG of anesthetized dogs and cats with neurologic disorders [4]. However, there have been few reported cases studied using both EEG and histopathology. The present paper describes a case of seized dog which showed abnormal EEG and revealed histopathologically to have suffered from meningoencephalitis.

A male obese Pug breed, 2 years and 9 months of age, weighing 10.2 kg showed accidental seizure in August, 1986 and was treated with drip infusion of lactated Ringer's solution and administered vitamin complex and steroid under the clinical diagnosis of heat stroke at a private animal hospital.

On September 20, about one month after the onset of the first abnormal sign, seizure occurred again and the dog was referred to the veterinary hospital of Yamaguchi University. According to the chief complaint, the convulsion was likely to be cramped in the fore and hind legs, though aura of convulsion didn't appeared. The previous history associated with the incidence of neurological disease had not been observed by the owner. Abnormal locomotion had not usually been observed but an occurrence of compulsive abnormal action of turning to the right was recognized on a day before. Walking test revealed that the dog misdirected toward the right direction. There were no abnormal findings in physical examination including spinal reflexes but the menace reaction and the light reflex of the left eye disappeared.

Complete blood counts and biochemical ex-

amination of serum were in the normal range except for high WBC counts (Table 1). Electrocardiogram showed also a normal pattern. These findings indicated the decline of left eyesight and the disorder of the central nervous system.

On September 21, the dog was examined with EEG by the modulated Redding's method under the sedation of xylazine (2 mg/kg, Bayer Japan Co.) [8]. The abnormal 6 Hz positive spikes of EEG were observed on the left frontal area of the cerebrum (Fig. 1), which had not been reported in veterinary medicine or animal electroencephalography. Those spikes were reported to appear in the patient with epilepsy in human beings [3], and therefore the dog was suspected to have epilepsy. Then Primidone (Mysolin, Dainihon Seiyaku Co, 12.5 mg/kg/day p.o.) was administered as anticonvulsant and the time-course of condition of the dog was observed.

On September 25, the fourth day after the first treatment, the 1.5 times as much anticonvulsant as the first therapeutic dose was administered because the seizure began to occur 3 times or more in a day. On October 2nd, after the administration of anticonvulsant, seizure occurred again, and on 13th, left side of limbs were cramped and showed dysfunction which continued thereafter.

On October 16, abnormal spikes of 6 Hz were observed again on right frontal area same as the previous EEG, while the X-ray examination of the head didn't show any abnormal pictures. The dog was subjected to euthanasia by the owner's request and the autopsy was performed.

Grossly, on the cross section through the diencephalon, the right ventricle was larger than the left one, making asymmetric appearance (Fig. 2). Histopathologically, spongy degeneration of cerebral cortex, irregular vacuoles and perivascular cuff were prominent in the right frontal lobe. Slight meningitis was also noted (Fig. 3).

Sarfaty *et al.* [7] investigated dogs' meningoencephalomyelitis and distemper with EEG, reporting that the change of EEG was lower

\*CORRESPONDENCE TO: GOTO, N., Department of Veterinary Pathology, Faculty of Agriculture, Tokyo University, Bunkyo-ku 113, Japan.

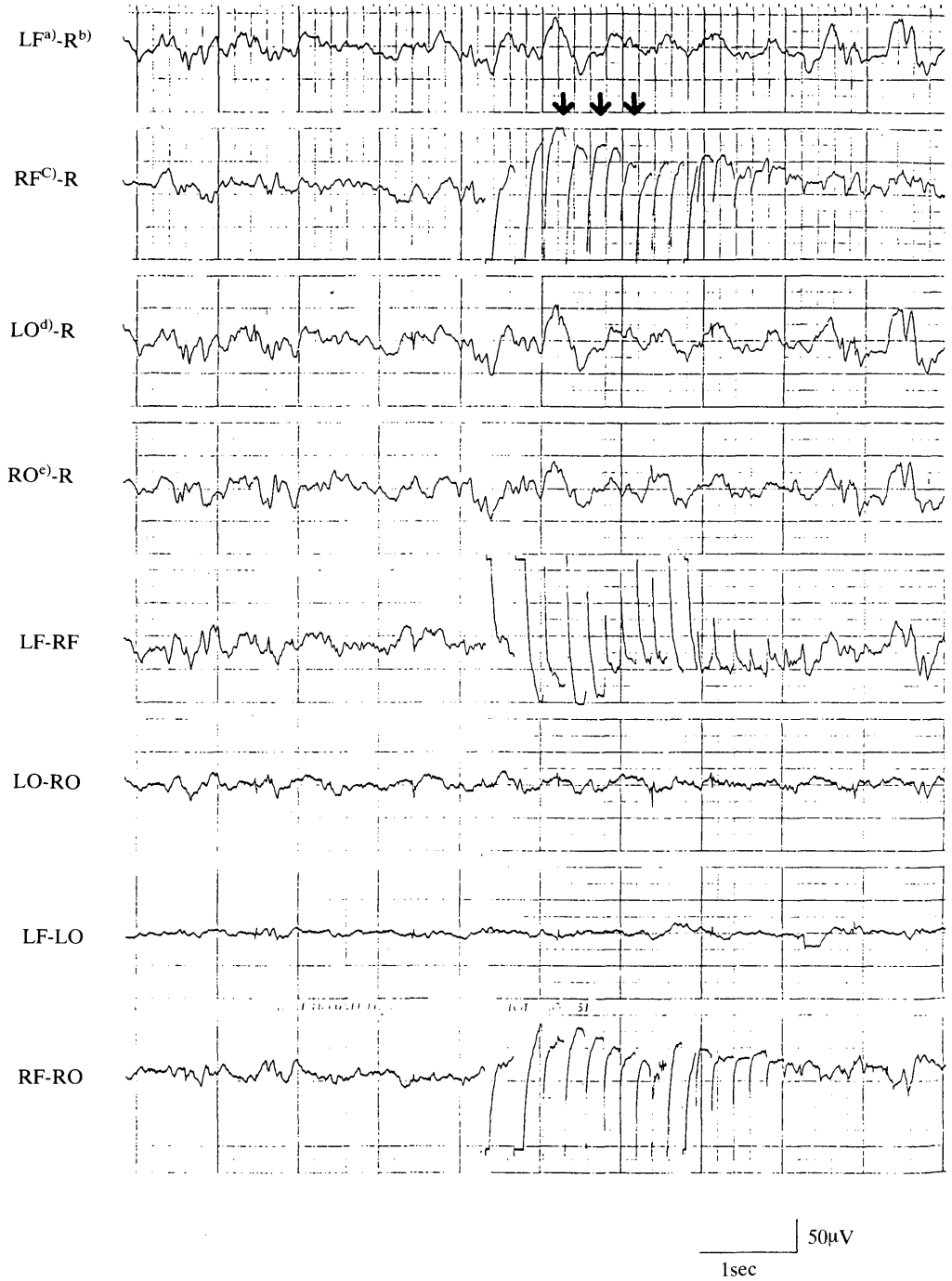


Fig. 1. Electroencephalogram of the patient appeared to six Hz positive spikes on the right frontal area. a) left frontal area, b) rhinal reference, c) right frontal area, d) left occipital area, e) right occipital area.

fre  
noi  
finc  
and  
intr  
app  
6  
repo  
appe  
brain  
classi  
thoug  
and t  
nality

Table 1. Hematological and laboratory data at the initial presentation

RBC ( $/\mu\text{l}$ )	$511 \times 10^4$	BUN (mg/dl)	13.5
WBC ( $/\mu\text{l}$ )	27200	GOT (R-F U)	20.4
PCV (%)	39	GPT (R-F U)	9.7
T. P. (mg/dl)	8.4	ALP (K-A U)	12.3
		GLU (mg/dl)	87
		Chol (mg/dl)	207
		Na (mEq/l)	147.4
		K (mEq/l)	3.8
		Ca (mg/dl)	10.0
		Mg (mg/dl)	1.8
		P (mg/dl)	5.0

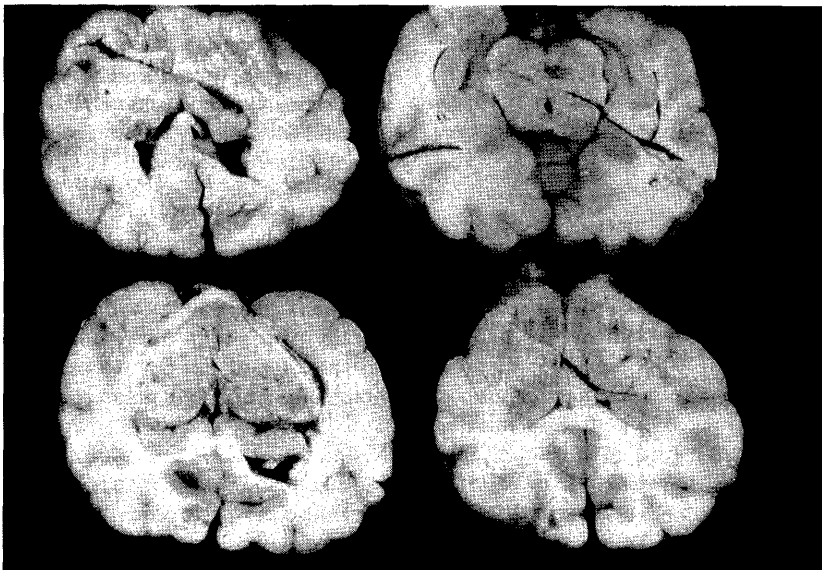


Fig. 2. Frontal sections of the patient's brain showing the asymmetric appearance caused by the hemilateral enlarged lateral ventricle.

frequency and higher voltages compared with the normal EEG patterns [7]. In this case, the findings mentioned by them were not recognized and the EEG patterns showing an increase in intracranial pressure or hydrocephalus did not appear though the ventricle enlarged.

6 Hz positive spikes on EEG have not been reported in animals. Provided that those spikes appear in human beings, abnormal state of the brain is suspected to occur and those spikes are classified into abnormal waves [3]. They are thought to appear in the patients with epilepsy and to reflect the disorder of behavior or personality [3]. They are commonly appeared on

occipital lobe in man [2], though they occurred on the frontal lobe in this case.

In the present case, 6 Hz positive spikes appeared in a hemilateral of the frontal lobe and the lesion of that area was ascertained histopathologically. Therefore the 6 Hz positive spikes might be associated with the lesion of the central nervous system of dogs. Although these positive spikes appeared in non-pyogenic meningoencephalitis in this case, whether they have clinical significance or not in human beings is now under discussion [2]. So further studies might be required to clarify the clinical significance of this abnormal spikes.

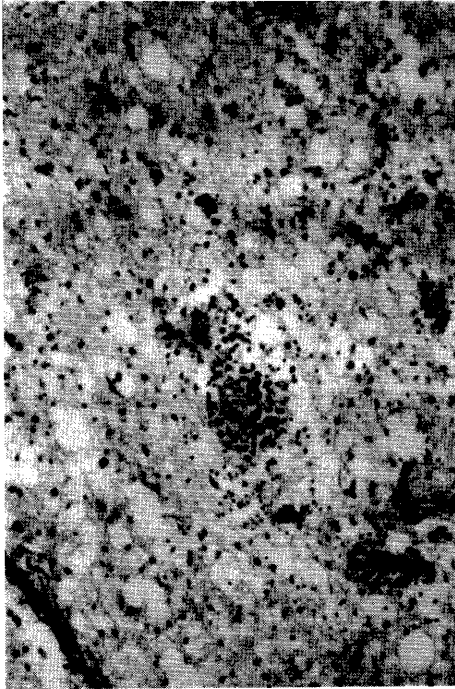


Fig. 3. Status spongiosus in the right frontal lobe of cerebrum with numerous irregular vacuoles and sparse neuropil. Inflammatory response was prominent.

#### REFERENCES

1. Chrisman, C. L. 1982. Special ancillary investigations. pp. 74-80. *In: Problems in Small Animal Neurology*, Lea & Febiger, Philadelphia.
2. Ebe, M. and Honma, I. 1979. A various kind of EEG pattern. pp. 36-57. *In: A text of EEG illustration*, Bunkoudou, Tokyo (in Japanese).
3. Ebe, M. and Honma, I. 1979. Abnormal EEG. pp. 102-153. *In: A text of EEG Illustration*, Bunkoudou, Tokyo (in Japanese).
4. Klemm, W. R. 1968. *Am. J. Vet. Res.* 29: 337-351.
5. Redding, R. W. 1978. Canine Electroencephalography. pp. 150-206. *In: Canine Neurology*, 3rd ed. (Hoerlein, B. F. ed.), W. B. Saunders, Philadelphia.
6. Redding, R. W. and Knecht, C. E. 1984. *Atlas of Electroencephalography in the Dog and Cat*. Praeger Publishers, New York.
7. Sarfaty, D., Carrillo, J. M., and Greenlee, P. G. 1986. *J. Am. Vet. Med. Assoc.* 188: 387-392.
8. Tourai, K., Senba, H., Sasaki, N., Tokuriki, M., Ohashi, F., Takeuchi, A., and Usui, K. 1985. *Jpn. J. Vet. Sci.* 47: 459-463.

#### 要 約

発作を主訴とする犬の電気生理学および病理学的研究(短報): 宇塚雄次・中畑功一郎・竹田良子・後藤直彰<sup>1)</sup>(山口大学農学部家畜内科学教室, <sup>1)</sup>家畜病理学教室)——発作を主訴とする犬の脳波検査を実施したところ、6 Hz 陽性棘波群が右前頭部に出現した。この異常脳波はヒトでもその臨床的意義が明らかとなっていないが、患犬の病理学的検査では、右側側脳室の片側性拡張と、異常脳波出現部位の皮質で非化膿性髄膜炎の存在が実証された。従って、6 Hz 陽性棘波群は、犬においても中枢神経系の異常を示す一つの診断基準と成りうることが示唆された。