

超音波エコー画像診断法によるモルモットの妊娠診断

誌名	Japanese journal of veterinary science
ISSN	00215295
著者	稲葉, 俊夫 森, 純一
巻/号	48巻3号
掲載ページ	p. 615-618
発行年月	1986年6月

—NOTE—

Use of Echography in Guinea Pigs for Pregnancy Diagnosis

Toshio INABA, and Junichi MORI

Department of Animal Reproduction, College of Agriculture, University of Osaka Prefecture, Sakai, Osaka 591, Japan

(Received 25 November 1985/Accepted 3 March 1986)

ABSTRACT. A real-time ultrasound scanner was used for pregnancy diagnosis in guinea pigs. The images of fluid-filled round uteri were recognized first on the echograph after day 16 of gestation. Accuracy of the diagnosis approached 100% on day 19 of gestation and the high accuracy was maintained throughout pregnancy period. After day 34 the fetal spine and the beating heart could be observed, and the death of fetuses was able to diagnose. Gestational age could be estimated by measuring the uterine diameter. Litter size also could be estimated with the accuracy of 81%. A real-time ultrasound might be used for the diagnosis of guinea pig pregnancy as an accurate, rapid and easy method.—**KEY WORDS:** guinea pig, pregnancy diagnosis, ultrasound.

Jpn. J. Vet. Sci. 48(3): 615–618, 1986

The guinea pig is widely used as an experimental model in the study of human medicine. However, conclusive diagnosis of pregnancy in guinea pigs at their early stage of pregnancy has not been available. Recently, ultrasound has become well established as an imaging method for use in human medicine, especially in obstetrics [4]. In veterinary medicine, ultrasound is used experimentally in small animals such as dogs [2], cats [5], and rats [1], but this method has not been applied to guinea pigs. In the present study, a real-time ultrasound equipment was used to diagnose pregnancy and to determine fetal age and litter size in guinea pigs.

A total of 50 Hartley strain guinea pigs from a conventional colony was used. At the time of estrus, the guinea pigs were mated. Day 0 of pregnancy was designated the day of mating. After mating, the guinea pigs were tested daily for the diagnosis of pregnancy by a real-time ultrasound scanner (EUB-25M Hitachi, Tokyo) with a 61 mm, 5 MHz linear array transducer (focusing depth 4 cm). Before echographic examination, each guinea pig was anesthetized with ether. The tip of

the probe was first covered with a water soluble gel before being applied to the lower flank of the animal. Pregnancy and non-pregnancy were finally determined by detecting the delivery. The longest diameter of the fluid-filled uterine lumen was measured for the estimation of fetal age. Relationships between fetal age and the measurements recorded were established using standard regression techniques. Litter size was estimated between day 25 and 40 of gestation by echography.

Scanned pictures of non-pregnant or pregnant guinea pigs before day 15 of gestation displayed no images of uteri as illustrated in Fig. 1A. On day 16 the images of fluid-filled round uteri were recognized first in three out of eighteen guinea pigs examined and they were diagnosed as pregnant (Fig. 1B). Of the remaining 15 diagnosed as "non-pregnant", twelve were pregnant. On day 18, percentage of correct diagnosis increased to 83% (Table 1) and on day 19 it reached 100% (12/12). Accuracy of the diagnosis using this method was one hundred %, thereafter. Images of fetuses were seen in the gravid uterus on the echograph after day 25 of gestation

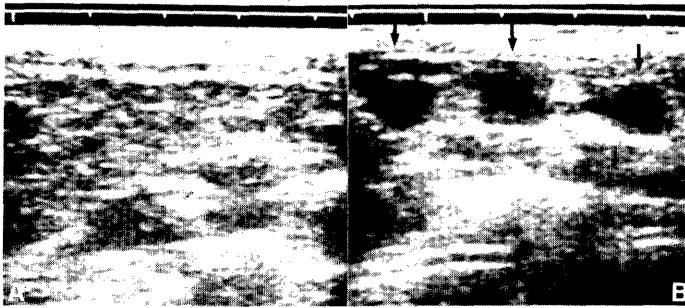


Fig. 1. (A) Scan of a pregnant guinea pig at day 14 of gestation. No images of the uterus are displayed. (B) Scan of a pregnant guinea pig at day 16 of gestation. The images of gravid uterus are visible (arrows).

Table 1. Accuracy of pregnancy diagnosis by ultrasonic echography

Day after mating ^{a)}	No. of guinea pigs examined	Diagnosis				Final percentage of correct diagnosis (%)
		"Pregnant"		"Non-pregnant"		
		No. of guinea pigs	No. of correct diagnosis	No. of guinea pigs	No. of correct diagnosis	
<15	23	0	0	23	4	17
16	18	3	3	15	3	33
17	14	7	7	7	3	71
18	12	8	8	4	2	83
19	12	9	9	3	3	100
>20	37	34	34	3	3	100

a) Day 0 = Day of mating.

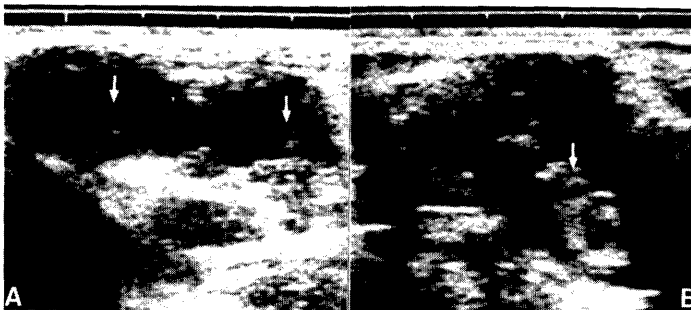


Fig. 2. (A) Scan of a pregnant guinea pig at day 25 of gestation showing the presence of two fetuses in the gravid uterus (arrows). (B) Scan of a pregnant guinea pig at day 34 of gestation. Heart movement can be seen on real-time (arrow).

(see Fig. 2A). After day 34 the fetal spine and the beating heart could be observed (Fig. 2B), and it was possible to diagnose fetal-death. The guinea pigs used in the present

experiments delivered their young between days 60 and 69.

Changes in the mean diameter of the uterine lumen during pregnancy period are pre-

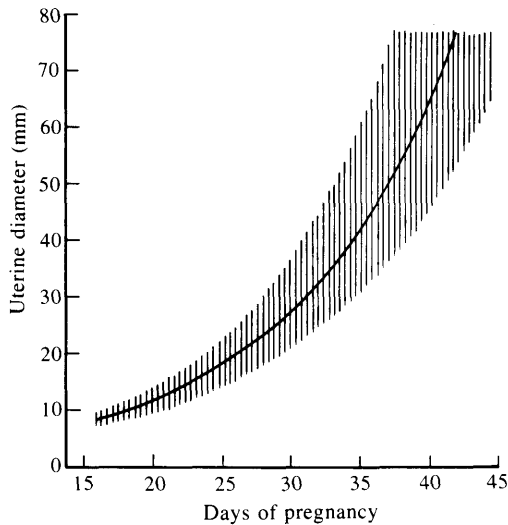


Fig. 3. Changes in the mean diameter of the uterine lumen during pregnancy period. The uterine diameter increased logarithmically ($\log Y=0.0855X+0.753$, X =days). The straight line indicates mean value and the shaded area represents 95% confidence intervals ($n=82$).

sented in Fig. 3. The uterine diameter increased logarithmically ($\log Y=0.0855X+0.753$, where Y was the uterine diameter and X was the day of pregnancy). The correlation coefficients were highly significant ($r=0.984$, $p<0.001$).

The results of an estimation of the litter size in the pregnant guinea pigs are presented in Table 2. Average litter size of guinea pigs was 3.0 ± 0.2 . The percentage of the litter sizes at parturition to those estimated by echography were 50–100% (average 81%). The number of fetuses was easier to estimate early in pregnancy than later stage, when fetal bodies were too big to count reliably.

The pregnancy diagnosis in the guinea pig has been the subject of speculation. The detection of sperm in vagina is not a reliable index of pregnancy [3]. Clinical examination by the abdominal palpation of the uterus is the most widely used method for diagnosing

Table 2. Estimation of litter size in guinea pigs by ultrasonic echography

Estimated litter size	No. of guinea pigs examined	No. of correct diagnosis (%)
1	1	1 (100)
2	5	4 (80)
3	10	8 (80)
4	3	3 (100)
5	2	1 (50)
Total	21	17 (81)

pregnancy in the guinea pig. Enlargement of the uterus, as an indication of pregnancy, can be detected in guinea pigs after day 30 of gestation [3]. However, fetuses in the uterus can not be palpated before day 40 of pregnancy.

In the present study, the gravid uterus of guinea pigs was clearly demonstrated using a real-time ultrasound as early as day 19 of gestation. Food contents and bowel gas did not impede the examination and the movement of the transducer did not cause any remarkable distress.

The present study indicates that a real-time ultrasound can be applied in guinea pig pregnancy diagnosis as an accurate, rapid and easy method.

REFERENCES

1. Inaba, T., and Inoue, A. 1985. *Jpn. J. Vet. Sci.* 47: 523–525.
2. Inaba, T., Matsui, N., Shimizu, R., and Imori, T. 1984. *Vet. Rec.* 115: 276–277.
3. Kometa, K. 1983. pp. 214–217. *In: Handbook of experimental animal* (Nagasawa, H., Fujiwara, K., Maejima, K., Matsushita, H., Yamada, J., and Yokoyama, A. eds.), Yokendo, Tokyo (in Japanese).
4. Pittaway, D. E., Wentz, A. C., Maxson, W. S., Herbert, C., Daniell, J., and Fleischer, A. C. 1985. *Fertil. Steril.* 44: 190–194.
5. Vondruska, J. F. 1983. *Vet. Med. Small Anim. Clin.* 78: 1225–1230.

要 約

超音波エコー画像診断法によるモルモットの妊娠診断（短報）：稲葉俊夫・森 純一（大阪府立大学農学部家畜臨床繁殖学教室）——超音波エコー画像診断装置を用いてモルモットの妊娠診断法の検討を行った。妊娠モルモットの子宮腔は交配後16日頃から円形に腫大しはじめ、19日以降は妊娠診断可能であった。妊娠34日を過ぎると、胎仔の心臓の動きが観察でき、生死判定が可能であった。子宮腔の直径から胎齢の推定が可能であり、胎仔数は81%の正確度で予測できた。