

## 矮小硬殻卵の連続産出鶏における解剖的観察

誌名	琉球大学農学部学術報告 = The science bulletin of the College of Agriculture, University of the Ryukyus
ISSN	03704246
著者	仲田, 正 古謝, 瑞幸
巻/号	34号
掲載ページ	p. 29-35
発行年月	1987年12月

## Anatomical Observations in Hens which Had Continuously Laid the Hard - Shelled Dwarf Eggs

Tadashi NAKADA\* & Zuiko KOJA\*\*

### Summary

The shape and contents of the hard-shelled dwarf eggs of Single White Leghorn were examined. Autopsy was performed on 32 hens which had continuously laid the hard-shelled dwarf eggs to observe the state of their reproductive organs.

There were two distinct types of the dwarf eggs with respect to their shape: The prolate-spheroidal type, similar to a normal egg; and the cylindrical type, much longer in proportion to the breadth. These dwarf eggs contained a small yolk or no yolk but the nucleus around which albumen was formed in various forms. Autopsy revealed that in all hens the body cavities contained a yellow fluid which was chiefly yolk which had escaped from the vitelline membrane of the ovum ovulated. The number of the partially ruptured vitelline membrane was the same to that of the hard-shelled dwarf eggs produced. The production of the dwarf egg was closely associated with ovulation. In case of the oviduct of these hens, the anterior portion of magnum and the oviducal ligament in the region of infundibulum were obviously abnormalities. Thick and hard tumorous or scar tissue at the oviducal wall of magnum constricted the lumen of the oviduct and prevented the passage of a normal egg, but allowed the passage of a small piece of yolk or a fragment of albumen. At the time of autopsy it was observed that a large cyst at the oviducal ligament had been engulfed by infundibulum. It seemed therefore that a large cyst directly blocked the entrance of a normal yolk by closing the mouth of the oviduct. From these autopsy records, it was assumed that the yolk which had entered the oviduct was unable to pass the obstructive portion and a large fragmental yolk or entire yolk was expelled into the body cavity. In this case, a part of yolk picked up by the oviduct would have become a nucleus for the formation of the egg envelopes. As the result, the hard-shelled dwarf egg with a small yolk was laid. On the other hand, when the mechanical stimulation to the albumen secreting region of the yolk before breaking or

---

\* Department of Animal Science, College of Agriculture, University of the Ryukyus

\*\* Agricultural experiment station

Sci. Bull. Coll. Agr. Univ. Ryukyus 34: 29 ~ 35 (1987)

cyst prior to their expulsion from the oviduct into the body cavity was synchronized with ovulation, the secretion activity for the egg formation in the oviduct was significantly activated. When the oviduct was in such a specific state, the complete set of egg envelopes was stimulated by the small lumps of hardened albumen, which in these cases seemed to be the nucleus of the dwarf egg. As the result of this, the hard-shelled dwarf eggs without yolk would have been produced.

### Introduction

It is well known that hens or birds other than the domestic fowl occasionally produce significantly small eggs. These small eggs are called by various names<sup>5)</sup> as "cock eggs", "luck eggs", "witch eggs", "dwarf eggs", etc. In this paper "dwarf eggs", which is somewhat descriptive, is used as the name of these small eggs. The dwarf eggs are sometimes hard- or soft-shelled eggs with or without yolk<sup>3)</sup>. The author et al (1980)<sup>3)</sup> have indicated that the production of hard-shelled yolkless dwarf eggs is closely associated with the internal ovulation into the body cavity. Furthermore, they successfully induced well calcified dwarf eggs similar to those produced naturally by the insertion of artificial yolk into the oviduct near the time of natural or induced ovulation. It was, however, left as an unknown in hens which had naturally laid the hard-shelled dwarf egg, why the ovum ovulated was not passed through the full length of the oviduct and was extruded into the body cavity.

It is the purpose of the present paper to investigate (1) anatomical state of the reproductive organs in hens which had continuously laid the hard-shelled dwarf eggs; (2) the different types of dwarf eggs with respect to shape and contents.

### Materials and Methods

Thirty two Single White Leghorn hens (1.5 year old) laying continuously 3-6 hard-shelled dwarf eggs were obtained for five years from 1982 to 1986 at a Poultry Farm of Yonabaru-cho, Okinawa where about 20,000 laying hens had been kept. For the inspection of reproductive organs, all these hens were killed within one week after the lay of the last dwarf egg in a clutch. The dwarf eggs were weighed, and the length and breadth were also measured to calculate the egg shape index which was commonly employed as the index of resemblance in the contour of egg. The value is obtained by dividing the transverse diameter of the egg by the length and multiplying the result by 100. During the investigation the contents of 136 dwarf eggs were examined.

## Results

There were two types of the dwarf eggs with respect to their shape as shown in Fig. 1 : cylindrical and prolate-spheroidal types. The cylindrical eggs, which had the length much longer in proportion to the breadth, occurred much less frequently than the prolate-spheroidal types did. Only 6 of the 136 dwarf eggs (4.4 per cent) were the cylindrical types. The remaining eggs were the prolate-spheroidal types which were similar in shape to a normal egg. In comparison of the egg shape index between the two types, there was statistically a great difference while the values of both the prolate-spheroidal eggs and normal eggs were not statistically different.




Fig. 1. Prolate-spheroidal dwarf eggs                      Cylindrical dwarf eggs  
The largest egg in each of the two figures is a normal egg.

Egg contents as the nucleus around which the albumen was formed were classified as fractional yolk which had escaped from a vitelline membrane and no yolk with the nucleus which consist of a few strings of coagulating albumen, apparently untwisted chalazal threads and also sometimes lumps of hardened albumen (Fig. 2). From the results of Table 1, it was seen that 78.7 per cent of the eggs opened were fractional

Table 1 Classification of the dwarf eggs both as to shape and as to egg contents

Egg shape	No. of eggs	average shape index	Egg contents	
			yolkless	some yolk
Prolate-spheroidal	130	78.9 (75.1) *	23	107
Cylindrical	6	65.3	6	0

\* Egg shape index of normal egg

yolk without yolk membrane.

The remainder was yolkless.

At autopsy, it was found that all hens with the hard-shelled dwarf eggs were in normal healthy condition, except the oviduct. Their body cavities were filled with the yellow fluid of yolk. The partially ruptured vitelline membranes were found in the yolk fluid and the number of these membranes were same to those of the hard-shelled dwarf eggs produced previously. With the respect to the oviducts, it was found

that the wall of the anterior portion

of magnum or the oviducal ligament in the region of infundibulum were abnormal (Fig. 3).

Their abnormalities were observed tumorous or scar tissues in the oviducal wall of magnum and a large cyst which was filled chiefly with liquid at the oviducal ligament in infundibulum ( Table 2 ).

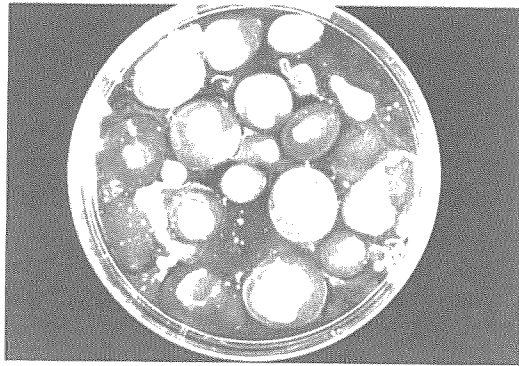
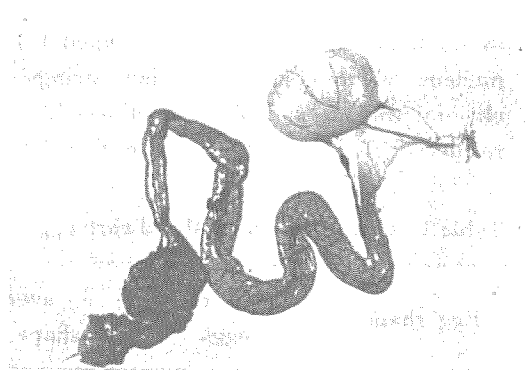

Fig. 2. Various forms of nucleus within the dwarf eggs




Fig. 3. Abnormal oviduct ;  
Tumor at the anterior portion  
of magnum



A cyst at the oviducal ligament

Table 2 Autopsy records of hens which had continuously laid dwarf eggs

No. of hens	Sex organs	Pathological condition
32	Ovary	Normal
	Oviduct	Tumorous tissue in the oviducal wall at the anterior portion of magnum ( 11 )
		Scar tissue in the anterior portion of magnum, at the site of a previous rupture ( 2 )
		A large cyst in the oviducal ligament of infundibulum ( 9 )

Number in parenthesis is hens with the pathological abnormalities

#### Discussion

In domestic fowl, the infundibulum of the oviduct becomes very active when ovulation approaches<sup>1)</sup>. This region advances, clasps the ovary as if to swallow it and then engulfs yolk ovulated. Such a functional activation of the region continues for about an hour before ovulation<sup>2)</sup>. When the infundibulum was in normally functional condition, it is able to engulf not only the yolk ovulated but also foreign bodies<sup>5)</sup> such as amber bead, wood or rubber, glass marble, agar, etc. However, the production of the hard-shelled dwarf eggs which contain foreign body as a nucleus is induced just when the insertion of artificial yolk of agar into the anterior portion of magnum is conducted near the time of ovulation, while it results in the production of soft-shelled egg when the artificial yolk is inserted far apart from the time of ovulation<sup>2, 6)</sup>. It is indicated that the effective stimulus for the formation of the egg envelopes possibly occurs behind the anterior portion of magnum. The hard-shelled dwarf eggs are also induced whenever a small agar is inserted in association with the time of ovulation<sup>3)</sup>. It has been postulated from this result that the timing of entering the yolk or yolk material into the oviduct in relation to ovulation is an important factor for the formation of a complete set of egg envelopes, even though its size is very small.

On autopsies in hens which had continuously laid the hard-shelled dwarf eggs, the body cavities were filled with a yellow fluid of the yolk which had come from vitelline membrane of the ovum ovulated. As the number of the vitelline membrane was the same as that of the dwarf eggs produced previously, it appeared that all of the hard-shelled dwarf eggs would be responsible for the occurrence of ovulation which was later extruded into the body cavity.

One may ask why the yolk ovulated fails to enter the oviduct in all hens with the dwarf eggs and results in intraovulation in the body cavity. The abnormalities like tumorous or scar tissue were observed at the upper oviduct. In cases of such

abnormalities at the oviducal wall in the anterior portion of magnum, in places the walls were thickened and hard and the caliber of the oviduct in these abnormal region were very constricted and locally narrow. It seemed accordingly that an ovum ovulated would have been broken by the propelling movement toward the abnormal region which formed a partial constriction, and would have been resulted in extrusion by anti-peristalsis initiated and entered the oviduct. It seemed probable that the normal yolk did not pass through the abnormal region because the lumen of the oviduct was narrower than the diameter of the normal egg, but allowed the passage of a small piece of yolk, a fragment of albumen which involved in the dwarf eggs as nucleus.

In a large cyst at the oviducal ligament, it was just engulfed by the infundibulum followed by closing the duct and it seemed therefore certain that the true yolk had failed in passing into body cavity as the result of the entrance prevention. The entrance of the cyst in the oviduct in synchronization with ovulation would have been induced some secretion of albumen becoming a central nucleus around which egg envelopes including shell are formed. The reason why the dwarf eggs are produced may be attributed the lesser stimulation of the oviduct wall by the small central nucleus such as a fragmental yolk or albumen than that by the true yolk.

#### References

1. Gilbert, A. B. 1971 Transport of the egg through the oviduct and oviposition. In *physiology and biochemistry of the domestic fowl*, Vol. 3 p 1345–1350, Academic Press, London
2. Nakada, T., Koja, Z. and Tokashiki, S. 1976 Influence of ovulation and gonadal hormones on shell formation in the domestic fowl, *Jpn. Poult. Sci.*, 13 : 169–175
3. Nakada, T., Tanaka, K. and Koga, O. 1980 Relationship between production of yolkless dwarf eggs and ovulation, *Jpn. Poult. Sci.*, 17 : 199–203
4. Pearl, R. and Curtis, M. R. 1916 Studies on the physiology of reproduction in the domestic fowl—XV Dwarf eggs, *J. Agr. Res.*, 6 : 977–1042
5. Romanoff, A. L. and Romanoff, A. J. 1949 Anomalies. In *Avian egg*, p255–307
6. Tanaka, K. 1976 A physiological study of egg shell formation in the domestic fowl with special reference to the initiation of secreting egg shell material, *Jpn. J. Zotech. Sci.* 47 : 385–392

## 矮小硬殻卵の連続産出鶏における解剖的観察

仲田 正・古謝瑞幸

## 要 約

産卵鶏において卵内に卵白片あるいは卵黄小片を有する矮小硬殻卵を連続的に産出する事例が観察された。今回、その産出原因を究明するため同産出鶏32羽を屠殺し、剖検した。また、産出された136個の矮小硬殻卵について、形状並びにその核成分について調べた。

剖検によると、腹腔内は排卵卵子から漏出した卵黄液で満たされ、漏出後の卵黄膜の数は産出された矮小硬殻卵の数と一致することから、連続的な矮小硬殻卵の産出は排卵と密接に関連した事象であることが推察された。

生殖器官のうち卵巣は全例共正常であったが、逆に卵管は全例に形態的異常を認めた。すなわち、卵管膨大部前部の卵管壁においては腫瘍や瘢痕組織が観察され、卵管漏斗部の卵管靭帯には水腫の付着が認められた。腫瘍並びに瘢痕組織の存在する部位は極めて厚く、硬化しており、卵管腔が狭くなっていた。水腫はいずれの事例でも排卵直前には卵管へ取り込まれ、卵管口を封鎖していた。これら卵管における異常性によって、排卵卵子は卵管全長を通過することができず、卵形成の核にもなり得ず、その代り取り込みなどの刺激によって形成された卵白が核になったものと思われた。

矮小硬殻卵の殆どが長球状を呈し、一部は円柱状であった。核成分は、長球状のものでは殆どが球状の卵黄小片であったのに対し、円柱状では細長い糸状の卵白であった。このことから核のサイズが卵の大きさに、核の形状が卵の形状に関連すると思われた。